



# STUDY BOOKLET

— clinical research & case studies —

## **NSK Europe GmbH**

Elly-Beinhorn-Strasse 8  
65760 Eschborn  
Germany

[www.nsk-europe.de](http://www.nsk-europe.de)

## **NSK United Kingdom Ltd.**

Office 5, Gateway 1000  
Arlington Business Park, Whittle Way  
Stevenage, SG1 2FP, UK

[www.nsk-uk.com](http://www.nsk-uk.com)

# TABLE OF CONTENT

Category

## Periodontology/Periodontal Therapy

### Function of air-abrasion device during open flap surgery in resective and regenerative periodontal therapy: case reports 3-4

Journal of Clinical Periodontology 2018 / F. Simon, J. Gángó, M. Kivovics, O. Németh  
[https://onlinelibrary.wiley.com/doi/10.1111/jcpe.261\\_12916](https://onlinelibrary.wiley.com/doi/10.1111/jcpe.261_12916)  
Department of Community Dentistry, Semmelweis University, Budapest, Hungary

### Efficacy of subgingival air polishing in the non-surgical periodontal therapy of patient with chronic periodontitis (Pilot study) 5-6

Journal of Clinical Periodontology 2018 / L. Komlósi, P. Valyi  
[https://onlinelibrary.wiley.com/doi/10.1111/jcpe.420\\_12915](https://onlinelibrary.wiley.com/doi/10.1111/jcpe.420_12915)  
Department of Periodontology Faculty of Dentistry, Szeged, Hungary

Category

## Implant Dentistry/Peri-implant Diseases

### Air-abrasive cleaning and widening the keratinized gingiva with e-ctg during surgical peri-implantitis treatment: case reports 7-8

Journal of Clinical Periodontology 2018 / J. Gángó, F. Simon, O. Németh, M. Kivovics  
[https://onlinelibrary.wiley.com/doi/10.1111/jcpe.461\\_12916](https://onlinelibrary.wiley.com/doi/10.1111/jcpe.461_12916)  
Department of Community Dentistry, Semmelweis University, Budapest, Hungary

### Occurrences of perio-implant inflammation and their treatment with the NSK Perio-Mate Air Polishing device 9-12

Dr. Júlia Gángó, Dr. Rebeka Vadócz, Dr. Dóra Derdák, Dr. Orsolya Németh, Dr. Márton Kivovics  
Department of Community Dentistry, Semmelweis University, Budapest, Hungary

Category

## Implant Dentistry/Bone regeneration therapies

### Bony wall window repositioning in sinus floor elevation: a comparative randomized, controlled trial 13-14

B. Molnár, Z. Papp, A. Martin, K. Orbán, P. Windisch  
Department of Periodontology, Semmelweis University, Budapest, Hungary

### Bone splitting augmentation with NSK VarioSurg3, case study 15-19

Jozsef Szalma DMD, PhD, Habil.  
Department of Oral and Maxillofacial Surgery University of Pécs, Pécs, Hungary

### Onlay graft with NSK VarioSurg3, case study 21-25

Jozsef Szalma DMD, PhD, Habil.  
Department of Oral and Maxillofacial Surgery University of Pécs, Pécs, Hungary

**Category** Periodontology/Periodontal Therapy

**Related product** Varios Combi Pro

## Function of air-abrasion device during open flap surgery in resective and regenerative periodontal therapy : case reports

Journal of Clinical Periodontology 2018 / F. Simon, J. Gángó, M. Kivovics, O. Németh  
[https://onlinelibrary.wiley.com/doi/10.1111/jcpe.261\\_12916](https://onlinelibrary.wiley.com/doi/10.1111/jcpe.261_12916)  
Department of Community Dentistry, Semmelweis University, Budapest, Hungary

### Background

One of the basic pillars of periodontal surgery is open flap surgery, which preserves the regeneration skill of the periodontium. The aim of this case report is to present a novel approach to the effects of air polishing device (Varios Combi Pro – NSK) usage during periodontal open flap surgery with a primary focus on periodontal attachment and regeneration.

### Description of clinical procedure

The observed group of cases contained of patients with chronic periodontitis, deeper than 4 mm sockets. Periodontal parameters of each patient had been registered (PPD, GR, CAL, BoP, PI) two days pre-surgery and at the 3-months post-surgery appointment. After conservative therapy and motivating our subjects to perform ideal oral hygiene, they were prepared for open flap surgeries.

Every case was operated by the same surgical method by contouring flaps,

removing the granulation tissues with hand scalers and root surfaces were conditioned by air polishing device. Besides the same steps, in two cases, Emdogain® (Straumann) were applicated into defects. The risk of periodontal damage was minimized because the plastic nozzle tip of the air polishing is easily insertable on root surfaces. Furthermore, the device can be set in a proper periodontal function.

### Description of the outcomes

After 3 month healing period, the involved teeth showed absence of bleeding on probing. Average pocket depth reduction was 3 mm. The clinical attachment gain in average was 3 mm. We observed slight (2 mm) gingival recession. These results indicate that using air polishing device provides plaque-free and homogenous but cemented root surfaces while periodontal ligaments might be properly preserved to give chance for periodontal regeneration.

## Efficacy of subgingival air polishing in the non-surgical periodontal therapy of patient with chronic periodontitis (Pilot study)

Journal of Clinical Periodontology 2018 / L. Komlósi, P. Valyi  
[https://onlinelibrary.wiley.com/doi/10.1111/jcpe.420\\_12915](https://onlinelibrary.wiley.com/doi/10.1111/jcpe.420_12915)  
Department of Periodontology Faculty of Dentistry, Szeged, Hungary

### Background

The causal treatment of plaque-related periodontal conditions is the removal of the biofilm that forms on tooth surfaces and contains pathogen microorganisms. The efficacy of non-surgical periodontal therapy is currently considered to reach 84%, as the removal of deposits from subgingival area, thus the prevention of reinfections is extremely difficult. The novel air polishing technology, which is able to fill in microscopic gaps, was adapted for subgingival instrumentation a few years ago. The purpose of this study was to evaluate the efficacy of air polishing applied subgingivally through the measurement of clinical and microbiological parameters using a split-mouth design.

### Description of clinical procedure

In this randomized clinical trial 8 chronic periodontitis patients with a mean age of 51.4 years old were included. Subjects had to show a probing pocket depth (PPD) of  $\geq 4$  mm in case of at least 2 pockets per quadrant. Prior to treatment

clinical parameters were registered. Subsequently the treatment of PPD  $\geq 4$  mm pockets was carried out in a split-mouth design as follows: on the test side subgingival instrumentation was supplemented with glycine powder air polishing by Perio-Mate instrument (NSK, Japan), on the control side subgingival instrumentation was applied exclusively. The test and control sides were assigned randomly. Parameters were recorded at baseline and 1, 3, and 6 month following treatment. The collected data were analyzed with non-parametric tests (Wilcoxon test within groups and Mann-Whitney U test between groups) using Statistica 13.0 software.

### Description of the outcomes

Results: At 1 month no statistically significant differences were found between the test and control sides ( $p > 0.01$ ), nevertheless significant improvement was observed in all investigated parameters in both groups. Further significant improvement were found only in case of test sites at 3 month recall. Similar improvement was recorded at the test sides regardless difficult accessibility of individual sites (multi-rooted teeth, PPD $>5$  mm), but there was differences at the control sides: less improvement was observed at sites with difficulty in access to the root surface.

Conclusion: The additional effect of subgingival air polishing as a supplementary treatment was observed at 3 month visit. The method may be considered safe and a promising modality for repeated instrumentation in the clinical practice. However slight statistically differences supported the adjunctive effect, it seems to the subgingival air polishing methods improve the efficacy of mechanical instrumentation of root surface with difficult accessibility.

## Air-abrasive cleaning and widening the keratinized gingiva with e-ctg during surgical peri-implantitis treatment: case reports

Journal of Clinical Periodontology 2018 / J. Gángó, F. Simon, O. Németh, M. Kivovics  
[https://onlinelibrary.wiley.com/doi/10.1111/jcpe.461\\_12916](https://onlinelibrary.wiley.com/doi/10.1111/jcpe.461_12916)  
Department of Community Dentistry, Semmelweis University, Budapest, Hungary

### Background

The two case reports examine the effectiveness of surgical treatment combined with air polishing cleaning of the implant surface in case of three peri-implantitis lesions. Long-term results of insufficient keratinized gingiva around dental implants are peri-implant mucositis and periimplantitis in most cases. Minimizing surface alterations of the treated implant surfaces can be subserved by the chosen glycine-based air polishing powder.

### Description of clinical procedure

The surgeries included granulation tissue removal, gingival and bone contouring. Implant surfaces were cleaned using air polishing device with plastic tip (Varios Combi Pro, NSK), rinsed with physiological saline solution. In both cases the width of keratinized gingiva was inadequate so the buccal surfaces of the implants were covered with epithelialised connective tissue graft. In Case II the lesion was a three-walled intrabony defect, so a synthetic bone graft (In'Oss

Putty, Biomatlante) was used for augmentation. Clinical parameters (BoP, PPD, GR) had been registered at the time of the surgeries and at the 2-months post-surgery appointments. Both patients received an individualized oral hygiene training, which they maintained during the study.

### Description of outcomes

After the two-months follow-up there was no sign of suppuration in any of the cases. BoP parameters were registered at six point around each dental implant, and average PPD and CAL reductions were calculated. In Case I (two implants observed) BoP showed 100% reduction. The average PPD reduction was 2.84 mm (from 4.67 mm to 1.83 mm) and the mean CAL reduction was 2.33 mm (from 5.83 mm to 3.50 mm) on the buccal side. In Case II (one single implant observed) BoP showed 83% reduction, the average buccal PPD reduction was 3.00 mm (from 5.33 mm to 2.33 mm) and the mean buccal CAL reduction was 2.00 mm (from 6.33 mm to 4.33 mm). These results confirm the clinical relevance of surgical peri-implantitis treatment in consideration of the width and thickness of keratinised gingiva, and show the effectiveness of additional air polishing cleaning.

## Occurrences of perio-implant inflammation and their treatment with the NSK Perio-Mate Air Polishing device

Dr. Júlia Gángó, Dr. Rebeka Vadócz, Dr. Dóra Derdák, Dr. Orsolya Németh, Dr. Márton Kivovics  
Department of Community Dentistry, Semmelweis University, Budapest, Hungary

### Background

It is not a coincidence that dentists regularly face the complex task of treating inflammations around implants. The objective of our project group was twofold: (I) To assess the prevalence of grave inflammations (peri-implantitis) around overdenture-type prostheses of the mandible retained by two dental implants; and (II) To treat peri-implantitis both in the mandible and the maxilla with a combination of the air polishing device and local application of chlorhexidine digluconate, and to monitor the results by specific clinical parameters (BOP, PPD, CAL).

### Description of clinical procedure

Clinical Testing I: We have examined in our Institute the prevalence of grave inflammations around overdenture-type prosthesis of the mandible retained by two dental implants (peri-implantitis). Test subjects were selected randomly.

Clinical Testing II: Treating peri-implantitis both in the mandible and the

maxilla with a combination of the air polishing device and local application of chlorhexidine digluconate, and monitoring the results by specific clinical parameters (bleeding on probing-BOP, pocket probing depth-PPD, gingival recession-GR, clinical attachment level-CAL).

The applied substances and devices were the NSK Perio-Mate Air Polishing System and the Perio-Mate Powder, as well as a 0.2% chlorhexidine digluconate solution to treat the peri-implant pocket during mechanical cleansing at the clinic (2 mL/implant), with subsequent use at home for 7 days. We treated 23 processes of inflammation in the surroundings of implants in the course of our research with this method. The criteria for peri-implant inflammation were the following: detectable bleeding in the sulcus around the implant when probing the 6 surfaces of the implant with a periodontal probe (UNC-15 probe), where the clinical probing depth is at least 4 mm. After recording the PPD, GR and BOP values from around the implants, treatment commenced in local anaesthesia, and following air polishing cleaning we rinsed the peri-implant pocket with a 0.2% chlorhexidine digluconate solution. The patient was instructed and motivated to improve personal plaque control, which was examined at a check-up visit 2 weeks after the treatment. A follow-up visit at 4 weeks after the treatment included a repeated probe of the sulcus surrounding the implant, and the above clinical parameters were again recorded. Finally, we compared the initial and the 4-week findings.

### Description of outcomes

Clinical Testing I: From a total of 32 implants in the mandibles of the 16 test subjects, 3 implants had peri-implant inflammation (BOP positive, pus discharge,  $PPD \geq 4$  mm), which equals to a prevalence of 9.38%. This means that of the 32 examined implants, peri-implantitis occurred in 9.38% of cases, while 90.62% of cases showed no clinical sign of inflammation or signs of peri-implant mucositis in the soft and hard tissues surrounding the implants.

Clinical Testing II: Selecting maximum probe depths from PPD values of 23 implants, measured at 6 surfaces each, and calculating their averages, the initial value was PPD=5.870 mm and the control value was PPD=4.261 mm. Applying the Man-Whitney-U test, the difference between the medians of the initial and the control maximum pocket depth is significant ( $p<0.001$ ).

Due to gingival recession in several cases, CAL values may be more representative than PPD values ( $CAL=PPD+GR$ ). Selecting the highest CAL values per implant, calculated from values measured at 6 surfaces of the implants, and calculating their averages, the initial value was  $CAL=6.435$  mm and the control value was  $CAL=4.913$  mm. Applying the Man-Whitney-U test, the difference between the medians of the initial and the control maximum attachment loss is significant ( $p<0.001$ ).

When calculating the average of the 6 PPD values measured at the 6 surfaces of each implant, the initial value for all implants is PPD=4.181 mm and the control value is PPD=3.268 mm. Applying the Man-Whitney-U test, the difference between the medians of the initial and the control average pocket depth is significant ( $p<0.001$ ).

Similarly, calculating the average of CAL values measured at the 6 surfaces of each implant, the initial value for all implants is  $CAL=4.442$  mm and the control value is  $CAL=3.565$  mm. Applying the Man-Whitney-U test, the difference between the medians of the initial and the control average attachment loss is significant ( $p<0.001$ ).

In the initial testing, BOP (BOP+/-) measured in 23 implants at 6 surfaces each showed positivity in 95.65% of cases, that is the probing of the peri-implant sulcus resulted in bleeding in 95.65 percentage of examined surfaces, while this value was reduced to 34.06% at the 4-week check-up examination after the treatment.

It is essential for the long-term favourable outcome of implants to apply careful surgical and prosthetic work, regular check-up and supervision of patients, and early detection and prevention of any peri-implant inflammation. In this respect,

the air polishing device provides outstanding assistance with its simple and highly efficient use, making it one of the main pillars of everyday maintenance treatment for implants. Its efficacy is backed up by our research: the combined use of air polishing device and chlorhexidine digluconate solution resulted in a significant reduction in PPD, BOP and calculated CAL values when probing 23 implants at 6 surfaces each. The other portion of our clinical research shows that examining a group of 16 randomly selected subjects wearing lower overdenture-type dental prosthesis retained on implants, in altogether 32 implants there was a 9.38% occurrence of peri-implantitis.



**Category** **Implant Dentistry/  
Bone regeneration therapies**

**Related product** **VarioSurg3**

## **Bony wall window repositioning in sinus floor elevation: a comparative randomized, controlled trial**

B. Molnár, Z. Papp, A. Martin, K. Orbán, P. Windisch  
Department of Periodontology, Semmelweis University, Budapest, Hungary

### **Background**

Application of resorbable membranes for lateral bony window coverage delivers favorable results in sinus floor elevation by increased graft protection. The piezoelectric approach allows repositioning of the sinus bony wall as opposed to rotary window preparation. This may represent a valuable treatment alternative to the placement of collagen membranes for window coverage. Aim/Hypothesis: Our aim was to present the clinical, radiographic and histological results of a prospective, randomized, controlled trial on sinus bony wall repositioning compared to rotary window preparation with membrane coverage.

### **Description of clinical procedure**

Material and methods: 40 patients with at least one missing maxillary premolar/molar were treated by lateral maxillary sinus floor augmentation. Patients were randomized to Test (20 patients): piezoelectric window preparation (NSK VarioSurg3), bony wall repositioning. Control (20 patients) rotary window preparation, resorbable collagen membrane coverage (botiss collprotect).

A particulate xenograft (botiss cerabone) was utilized in both groups. Following clinical parameters were registered: duration of surgery, bony window, sinus mucosa preparation; number of sinus perforations; postoperative patient complaints by visual analogue scale (VAS); number of non-steroid inflammatory drugs (NSAID) taken. Qualitative radiographic evaluation was performed on pre- and postoperative CBCT scans. Hard tissues were analyzed histologically in biopsies retrieved at 6 months re-entry prior to implant placement (Straumann Tissue Level) by guided surgery (SMART Guide).

### **Description of outcomes**

Results: Duration of surgery was  $45 \pm 11$  min in test compared to  $49 \pm 11$  min in control. Duration of window preparation was  $4.45 \pm 1.36$  min in test compared to  $5.85 \pm 3.65$  min in control. Duration of mucosa elevation was  $5.8 \pm 3.3$  min in test compared to  $7.15 \pm 3.2$  min in control. Percentage of sinus perforations was 30% in test compared to 35% in control. VAS scores demonstrated lower morbidity in test compared to control:  $30.85 \pm 31.26$  vs.  $44.5 \pm 27.07$  on the day of surgery,  $19.75 \pm 26.09$  /  $29.40 \pm 26.6$  1 day-,  $12.9 \pm 20.31$  /  $24.8 \pm 23.17$  2 days-,  $9.5 \pm 16.5$  /  $17.63 \pm 21.13$  3 days postoperatively. Number of NSAID taken was  $1.42 \pm 0.61$  in test compared to  $1.75 \pm 0.91$  in control on the day of surgery,  $0.89 \pm 0.94$  /  $1.15 \pm 0.93$  1 day-,  $0.71 \pm 0.78$  /  $1.14 \pm 1.02$  2 days-,  $0.32 \pm 0.58$  /  $0.75 \pm 0.97$  3 days postoperatively. Differences were not significant. Radiographical and histological analysis confirmed favorable hard tissue reconstruction at all sites in both treatment groups.

Conclusion and clinical implications: Duration of surgery and window preparation, number of sinus perforations were lower following piezoelectric window preparation and bony wall repositioning with less patient morbidity. Quality and quantity of newly formed hard tissues were comparable to rotary preparation and membrane coverage. Piezoelectric preparation and sinus bony wall repositioning represents a valuable treatment alternative by eliminating the need for membrane application for window coverage in sinus floor elevation.



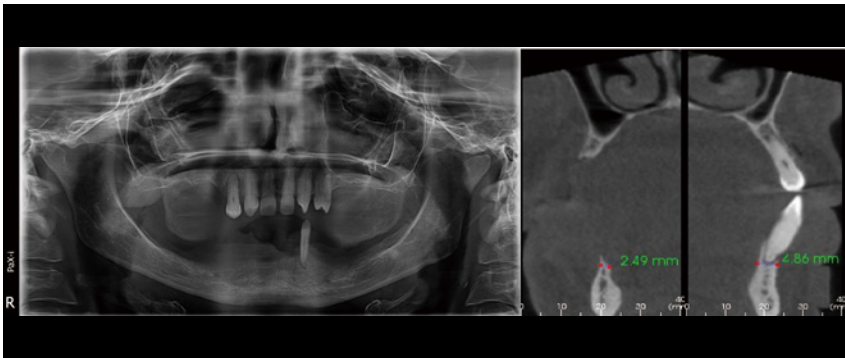
**Category** Implant Dentistry/  
Bone regeneration therapies

**Related product** VarioSurg3

## Bone splitting augmentation with NSK VarioSurg3, case study

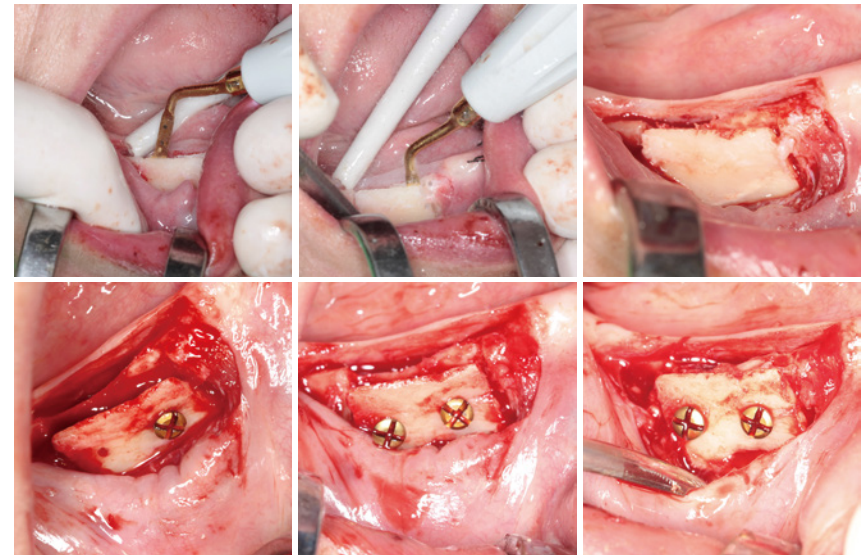
Jozsef Szalma DMD, PhD, Habil.  
Department of Oral and Maxillofacial Surgery University of Pécs, Pécs, Hungary

The initial mandibular subtotal edentulous situation. While left lower canine region shows minimally sufficient bone thickness (~4.8-4.9 mm) for a 3.3 mm  $\varnothing$  implant (BL, SLA, Straumann, Basel, Switzerland), the right bone amount is insufficient (~2.5 mm).

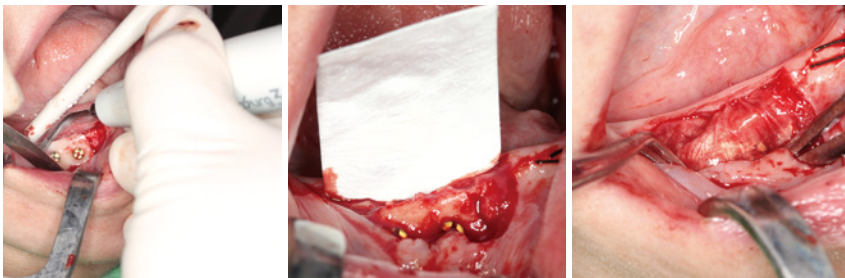


In infiltration local anesthesia, a mucoperiosteal flap was raised. After flap elevation, sagittal and mesial and distal vertical cuts were performed in the bone with the HSG1 saw tip.

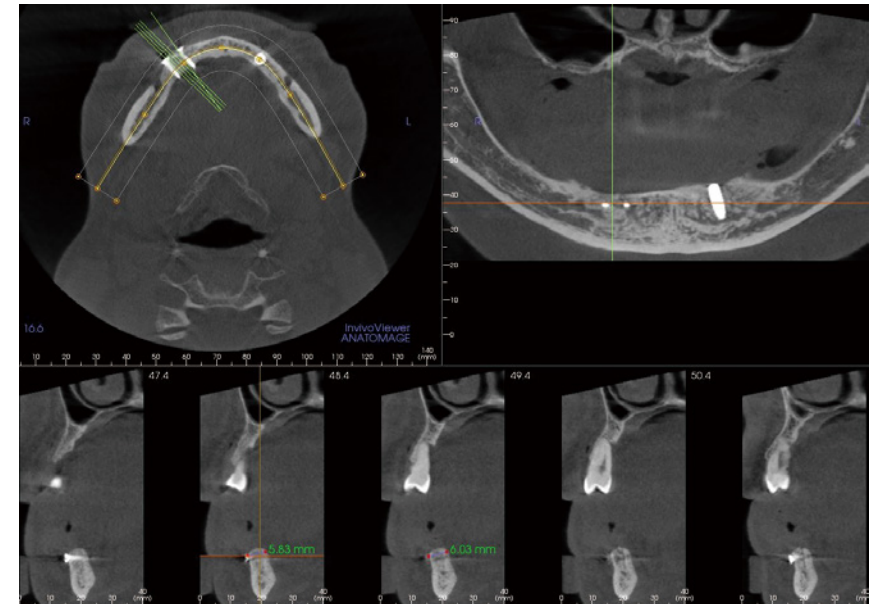
The buccal bone layer was opened carefully with a chisel and fixed in opened position with two lag screws (1.2 mm x 8 mm Depuy Synthes Hungary, Johnson & Johnson Medical Kft., Budapest, Hungary) after an adequate predrilling.



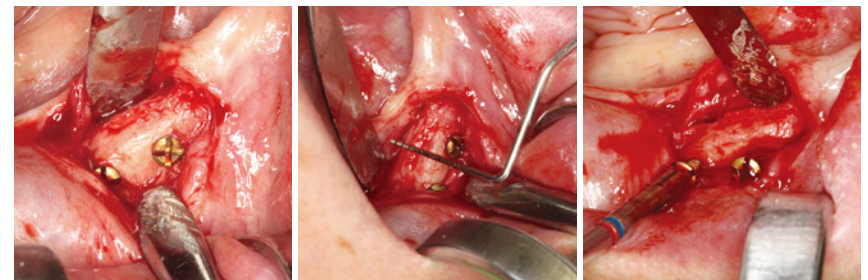
The edges of the opened bone lamella was grinded carefully with the diamond coated tip SG6D. In contrast with drills, using diamond tips for grinding is more secure for the augmented or fixed bone. Only own bone particles ("chips") was used, which was collected with the SG3 scraper tip during the contralateral implantation. A resorbable collagen membrane (2 x 3 cm Jason, Botiss Biomaterials GmbH, Zossen, Germany) was used to cover the augmented area.



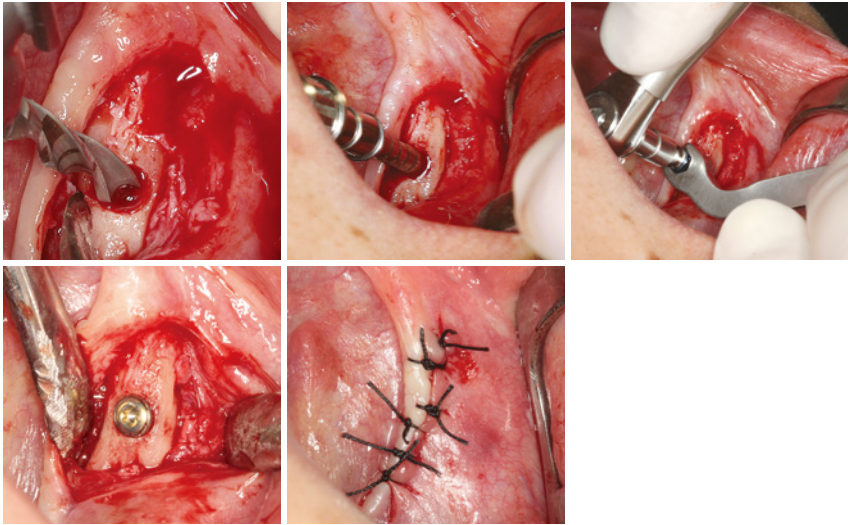
After six months, the augmented area shows correct bone healing and the bucco-lingual bone thickness was improved significantly (~6 mm).



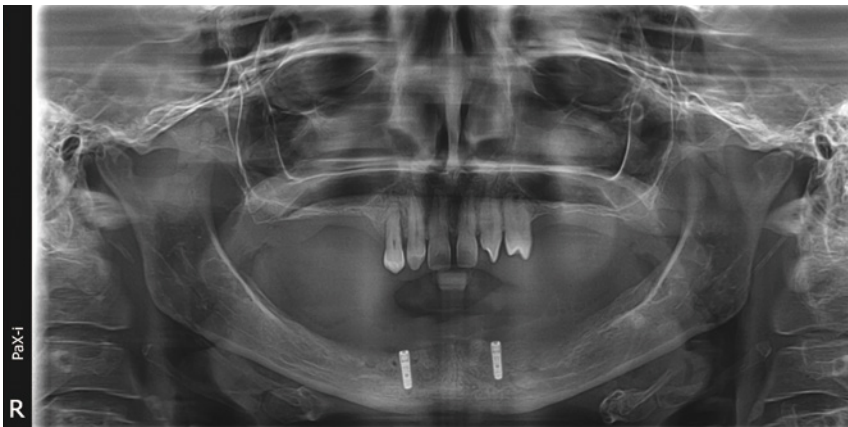In infiltration local anesthesia a crestal incision and mucoperiosteal flap elevation was performed. Intraoperatively optimal bone thickness was visible for a 3.3 mm Ø implant (BL, SLA, Straumann) placement. Before implant predrilling, the lag screws were removed.



The use of the tap was necessary, spite of the augmented new formed bone area, to reduce insertion torques to 25-30 Ncm values.



The inserted implants show acceptable angulations for a locator fixed removable prosthesis.





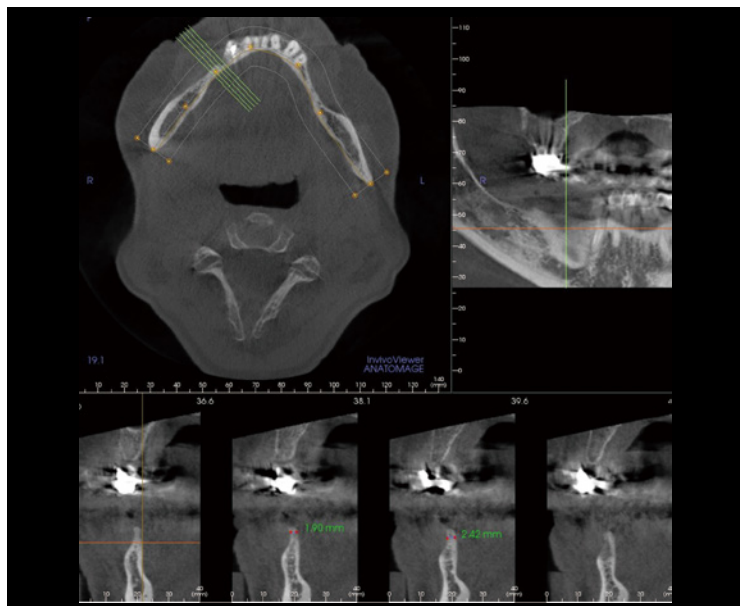
Category **Implant Dentistry/  
Bone regeneration therapies**

Related product **VarioSurg3**

## Onlay graft with NSK VarioSurg3, case study

Jozsef Szalma DMD, PhD, Habil.  
Department of Oral and Maxillofacial Surgery University of Pécs, Pécs, Hungary

The initial CBCT shows severe horizontal bone resorption at the right lower left lateral zone in the mandible. The average bone thickness was less than 3 mm.

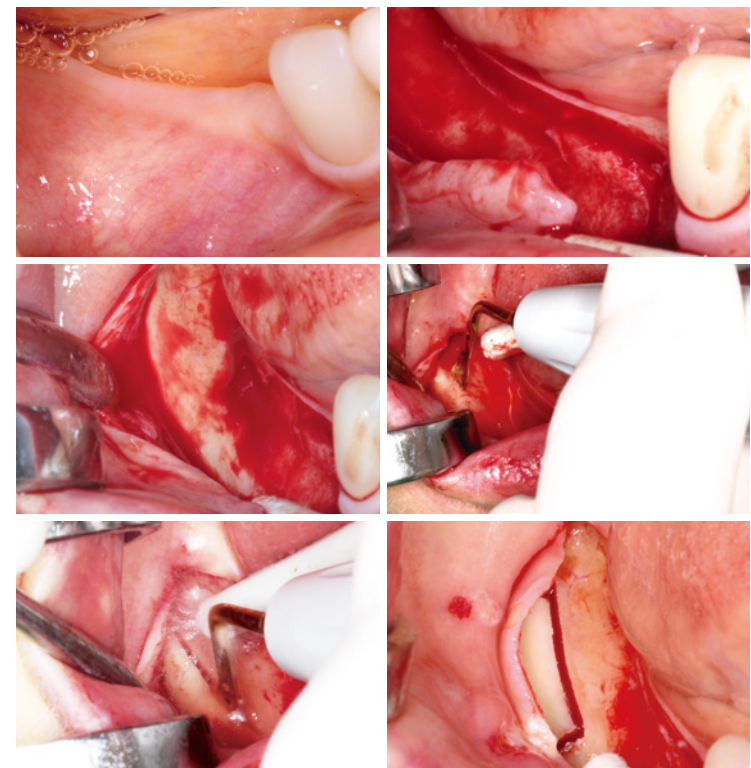


In infiltration and inferior alveolar nerve block anesthesia a mucoperiosteal flap was raised in the premolar, molar and retromolar area.

Authors decided to prepare an onlay graft from the same sided retromolar area of the mandible.

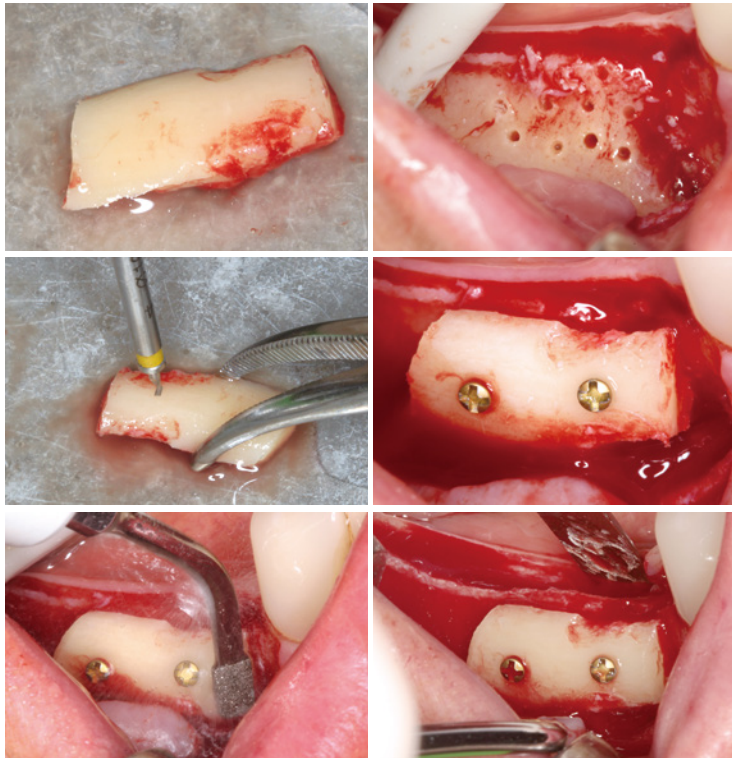
During osteotomy with the HSG1 saw tip the smooth and bloodless cut line is visible.

After releasing the onlay graft, the acceptor area was fenestrated, several times punched with small round drill to allow bleeding and cell migration from the bone.

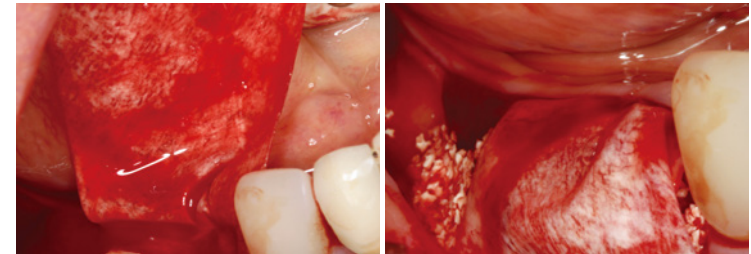


The onlay graft was predrilled and fixated with lag screws (1.2 mm x 8 mm Depuy Synthes Hungary, Johnson & Johnson Medical Kft., Budapest, Hungary).

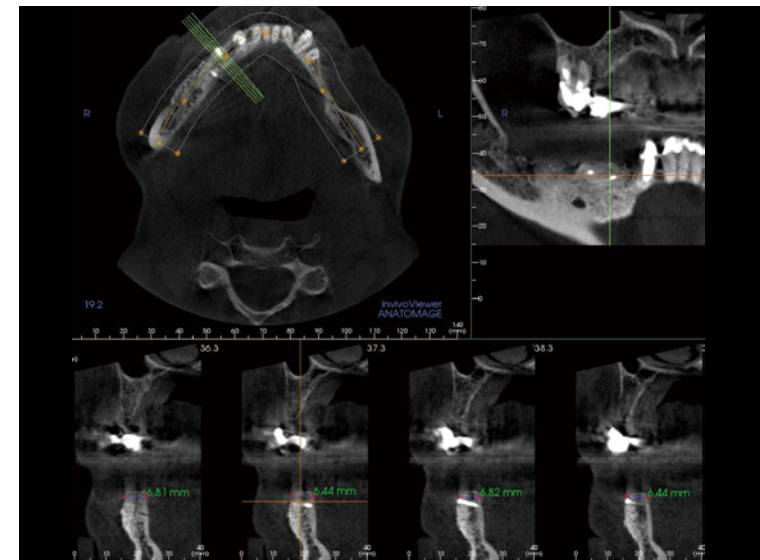
After the fixation, the sharp edges were smoothed with the diamond coated SG6D tip.



A 2 x 3 cm resorbable collagen membrane (Jason, Botiss Biomaterials GmbH, Zossen, Germany) was fixed with resorbable sutures lingually and bovine xenograft bone augmentation particles were used to fill incongruences between graft and acceptor site (Cerabone, Botiss Biomaterials GmbH, Zossen, Germany).



Six months later, a significant improvement (> 6 mm) in bone thickness was seen on postoperative CBCT.



Two implants (BL, SLActive, Straumann, Basel, Switzerland) were inserted in the grafted mandible. The prosthetic plan was a screw retained lateral bridge, fixed on the two implants.

